A Critical Review of the Role of the Proposed VMpo Nucleus in Pain

William D. Willis, Jr,* Xijing Zhang,† Christopher N. Honda,† and Glenn J. Giesler, Jr†

Abstract: The evidence presented by Craig and his colleagues for an important projection from lamina I spinothalamic tract neurons to a renamed thalamic nucleus (the posterior part of the ventral medial nucleus or VMpo), as well as to the ventrocaudal medial dorsal and the ventral posterior inferior thalamic nuclei, is critically reviewed. Of particular concern is the denial of an important nociceptive lamina I projection to the ventrobasal complex. Contrary evidence is reviewed that strongly favors a role of spinothalamic projections from both lamina I and deep layers of the dorsal horn to the ventrobasal complex and other thalamic nuclei and from there to the SI and SII somatosensory cortices in the sensory-discriminative processing of pain and temperature information.

© 2002 by the American Pain Society

Key words: *Pain, temperature sensation, spinothalamocortical pain system.*

Craig and his colleagues[15,40] have recently proposed the existence of a novel and potentially important nociceptive and thermoreceptive spinothalamocortical projection system in primates, including humans. This hypothetical pathway is summarized in Fig 1. It consists of a projection from lamina I of the spinal cord dorsal horn to 3 thalamic nuclei: the posterior part of a newly described ventral medial thalamic nucleus (VMpo), the ventral caudal part of the medial dorsal nucleus (MDvc), and the ventral posterior inferior nucleus (VPI). The proposed VMpo nucleus is thought to project to the dorsal anterior insular cortex and weakly to area 3a of the SI somatosensory cortex, the VPI nucleus to the SII somatosensory cortex, and MDvc to area 24c of the anterior cingulate cortex. The SI and SII somatosensory cortices, insula, and anterior cingulate gyrus have all been implicated in pain processing by recent imaging studies,[26,28,36,45,58,67,68,106,114] as have a number of other cortical and subcortical structures. Curiously, the scheme that has been proposed by Craig and his colleagues seems to dismiss the possibility of an important role of a lamina I projection to the ventral posterior lateral (VPL) and ventral posterior medial (VPM) nuclei (Fig 1). Furthermore, it does not address in a satisfactory way the role of spinothalamic projections from deeper layers of the spinal cord gray matter, and it does not deal with pain-related projections of other ascending pathways, some of which bypass the thalamus.

In their initial study, Craig et al[40] injected the anterograde tracer, *Phaseolus vulgaris* leukoagglutinin (PHA-L), into lamina I in monkeys. Lamina I spinothalamic tract (STT) neurons were observed to project to a region in the posterior thalamus adjacent to the basal part of the ventral medial nucleus (the relay nucleus for vagal, solitary, and parabrachial input). Previous experts on the thalamus considered this part of the thalamus to be part of the posterior (Po) nuclear group,[64,93] but it was given a new name by Craig and associates, the posterior part of the ventral medial nucleus (VMpo). Sparser projections were also observed to end in the MDvc nucleus and in the VPI nucleus, but apparently few, if any, were seen in the VPL nucleus. Craig et al[40] recorded from neurons in the region of the proposed VMpo nucleus and found that 97% of the 87 somatosensory neurons characterized in this region were responsive to nociceptive or to cold stimuli. The neurons whose responses were illustrated had relatively small receptive fields on the tongue or hand. Neurons in VMpo showed graded responses to graded intensities of stimulation, and the nucleus had an anteroposterior topographic organization. Axons in this nucleus could be immunostained for calbindin, including some double-labeled terminals of lamina I STT cells. A calbindin-rich plexus was found in a similar part of the human thalamus, suggesting the presence of a VMpo nucleus in humans, as well as in monkeys.

The proposed human VMpo nucleus was described in

Received November 29, 2000; Revised May 29, 2001; Accepted May 29, 2001.

From the *Department of Anatomy & Neuroscience, University of Texas Medical Branch, Galveston, TX, and †Department of Neuroscience, University of Minnesota, Minneapolis, MN.

Address reprint requests to Wm. D. Willis, Jr, MD, PhD, Department of Anatomy & Neurosciences, University of Texas Medical Branch, 301 University Blvd, Galveston, TX 77555–1069. E-mail: wdwillis@utmb.edu

© 2002 by the American Pain Society

1526-5900/2002 $35.00/0

doi:10.1054/jpai.2002.122949

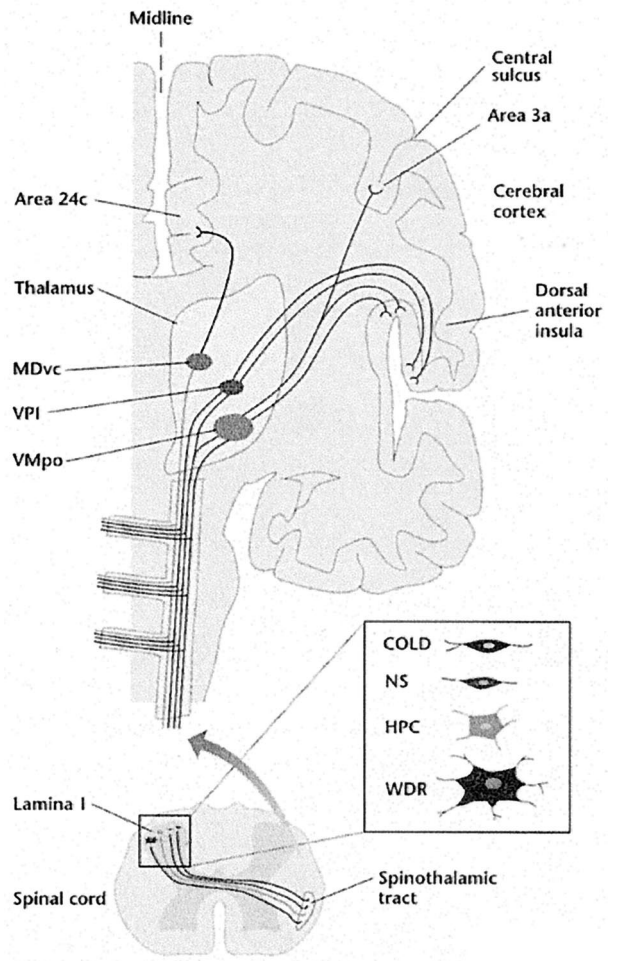

Figure 1. Proposed spinothalamocortical system for pain and temperature sensation. The projections of lamina I spinothalamic tract cells to the VMpo, MDvc, and VPI nuclei are shown. The VMpo nucleus is proposed to project to the dorsal anterior insula and perhaps also to area 3a of the SI cortex; VPI is shown to project to SII (not labeled); and a connection of MDvc to area 24c is depicted. The shapes of typical lamina I neurons responsive to cold, noxious stimuli (NS), heat, pinch and cold (HPC) stimuli, as well as of a WDR neuron, are seen in the inset. (From Perl ER: Getting a line on pain: Is it mediated by dedicated pathways? Nat Neurosci 1:177-178, 1998)

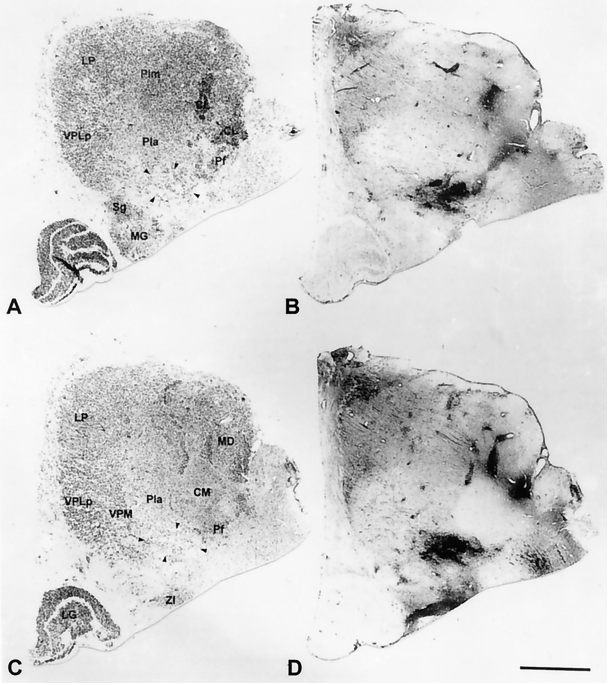

Figure 2. The identification of a VMpo nucleus in the human thalamus. In (A) and (C) are shown frontal sections separated by 0.8 mm through the posterior thalamus and stained for Nissl substance with thionin. The sections are oriented so that the midline is to the right and the top of the section is dorsal. The area occupied by the proposed VMpo nucleus is indicated by the arrowheads. The adjacent sections in (B) and (D) show the regions of the thalamus that were stained for calbindin with a monoclonal antibody obtained from Sigma. It should be noted that there is dense calbindin-like immunoreactivity in the area defined as the VMpo nucleus on the basis of this staining property. The scale represents 5 mm. CM, center median; Hl, Hm, lateral and medial habenular; LG, lateral geniculate; LD, lateral dorsal; LP, lateral posterior; MD, medial dorsal; Pla, anterior pulvinar; Plm, medial pulvinar; R, reticular; VPLp, posterior part of ventral posterior lateral; ZI, zona incerta. (From Blomqvist A, Zhang ET, Craig AD: Cytoarchitectonic and immunohistochemical characterization of a specific pain and temperature relay, the posterior portion of the ventral medial nucleus, in the human thalamus. Brain 123:601-619, 2000. Reproduced by permission of Oxford University Press.)

more detail by Blomqvist et al,[15] on the basis of the presence of the calbindin-immunoreactive axonal plexus noted by Craig et al.[40] According to Blomqvist et al, this nucleus is difficult to demarcate on the basis of cytoarchitecture. This difficulty presumably reflects the relatively few neuronal cell bodies that are found in this area in Nissl-stained sections (Fig 2). The VMpo nucleus was defined as an oval region that extends 3 to 3.5 mm mediolaterally, 2 mm dorsoventrally, and 2 mm rostrocaudally. Its position is posteromedial to the VPL and VPM nuclei, ventral to the anterior pulvinar and center median nuclei, lateral to the limitans and parafascicular nuclei, and dorsal to the medial geniculate nucleus (Fig 2). They considered the posterior (Po) complex to be separate and to include a narrow region separating VMpo from VPM/VPL and VPMpc (also known as VMb). Caudally, VMpo and suprageniculate neurons intermingle. Blomqvist et al state that the pattern of calbindin immunostaining revealed by the antibody they used (a monoclonal antibody produced by Sigma) and which was crucial for the identification of the nucleus was different from that observed by others using different antbodies.[93,108] According to Blomqvist et al, the proposed VMpo nucleus was included in the suprageniculate/posterior complex by Hirai and Jones[64] and Morel et al.[93] Blomqvist et al note that the proposed VMpo nucleus is located where spinal and lemniscal fibers enter the posterior thalamus.

The hypothetical spinothalamocortical projections proposed by Craig and colleagues that relay in the VMpo, MDvc, and VPI nuclei have been emphasized in several recent publications without a critical review of the evidence on which this proposal was based.[52,75,98,104] The roles of the VPL nucleus and SI cortex in the sensory-discriminative processing of pain and temperature are

clearly downplayed without justification. In the following, we examine the findings that led to the proposal of an important spinothalamocortical pain system that relays in the proposed VMpo nucleus, as well as in MDvc and VPI nuclei, and we weigh these findings against a much more substantial body of evidence that supports a major role in pain processing of the spinothalamocortical system that involves the VPL, VPM, VPI, Po, and central lateral (CL) nuclei.

Evidence Concerning the Spinothalamocortical Pain and Temperature System Proposed by Craig and Colleagues

The VMpo Nucleus

The morphologic identification of the proposed VMpo nucleus was based on the presence of a plexus of calbindin-immunostained axons. The identification of central nervous system nuclei is usually based on cytoarchitecture, rather than on fiber architecture, although the patterns of connections of a nucleus are obviously important. A major problem is that it is unclear to what extent the calbindin-positive axons in this case terminate in the proposed nucleus and to what extent these are axons of passage. No systematic study of this issue seems to have been done. The antibody used for the identification of a VMpo nucleus obtained from Sigma is no longer available. Therefore, other laboratories would be unable to conduct such a study.

Jones and his colleagues used a different antibody against calbindin and obtained a quite different staining pattern in the thalamus, and, unlike Craig and colleagues, Rausell et al[107] were unable to label spinothalamic axons for calbindin. The antibody used by the Jones laboratory did not recognize the axonal plexus described by Craig and his colleagues and instead demarcated the cell bodies of small calbindin-containing relay neurons that form a matrix zone in the VPL and Po nuclei in the region that receives the spinothalamic projection.[71] The matrix zone stains only weakly for cytochrome oxidase, and the neurons here are immunonegative for parvalbumin staining. This matrix zone extends throughout the VPL and VPM nuclei and into the VPMpc (VMb), VPI, anterior pulvinar, posterior, and ventral lateral nuclei. The remainder of the VPL, VPM, and posterior part of ventral lateral (VLp) nuclei form a core region that contains medium-sized and large relay neurons that immunostain for parvalbumin. This region is also rich in cytochrome oxidase and receives projections from the medial lemniscus and the principal nucleus of the trigeminal nerve.[71] The main function of the area of the human thalamus that has been termed the VMpo nucleus by Blomqvist, Craig, and their colleagues may be to serve as a passageway for axons that project to the VPL, VPM, VPI, Po, and other nuclei of the posterior thalamus.

Projection of Lamina I STT Cells to the Proposed VMpo Nucleus

Recordings were made by Dostrovsky and Craig[48] from a sample of 27 monkey lamina I STT cells that were antidromically activated from the region of what Craig and colleagues regard as the VMpo nucleus (Fig 3A). Of these, 20 were classified as cold cells (activated specifically by cooling stimuli; Fig 3B and D), 3 as multimodal (activated by heat, pinch, and cold), and 4 as nociceptive specific (activated by heat, pinch, or both). Thus, on the basis of this limited sample of recordings, the lamina I input to the region of VMpo seems to be thermoreceptive and nociceptive. Dostrovsky and Craig were unable to activate cold-responsive lamina I STT cells antidromically from the ventrobasal complex in 2 monkeys in which a stimulating electrode was placed in this region. They do not describe the responses of any of the lamina I STT cells that project to the VPL or VPI nuclei. However, it is conceivable that some of the lamina I cells in their sample actually projected elsewhere than to VMpo if the stimulating current spread to other nuclei or if they activated fibers of passage antidromically. It seems quite possible that the axons that were stimulated could have been passing through the region of the proposed VMpo nucleus on the way to the Po, VPI, or VPL nuclei. These possibilities are difficult to evaluate, because these investigators did not state what stimulus currents were used, they did not use the antidromic microstimulation mapping technique, and they showed the location of recording/stimulation sites in the thalamus near the proposed VMpo nucleus for only 1 of the animals (Fig 3E). Furthermore, there was no indication in their article of any attempt to determine whether STT cells in deeper layers of the dorsal horn or in other parts of the spinal cord gray matter could be activated antidromically from the region of the VMpo. If such antidromic responses had been observed, it would again be difficult to know whether this reflected the spread of stimulus current or, alternatively, a possible projection of STT cells from other parts of the spinal cord gray matter than lamina I to the region of the proposed VMpo nucleus, because it is not known whether such projections exist. For example, the retrograde tracing study of Zhang and Craig[128] offers no definitive evidence about this because the injections of tracer were not confined to the VMpo nucleus. Furthermore, there are no reports of specific anterograde tracing of the projections of lamina V STT cells to their terminals.

Craig[38] labeled neurons in lamina I of the monkey spinal cord with the anterograde tracer, PHAL, or with a dextran conjugate and followed the ascent of the axons of these neurons in the spinal cord. Many of the axons crossed to the contralateral side in the dorsal or ventral commissure of the same or immediately rostral segment, although a few axons ascended ipsilaterally (Fig 4). The axons that ascended contralaterally were concentrated in the middle of the lateral funiculus, although the axons shifted more ventrally at the level of the upper cervical cord. Axons from cervical levels were more medial in the

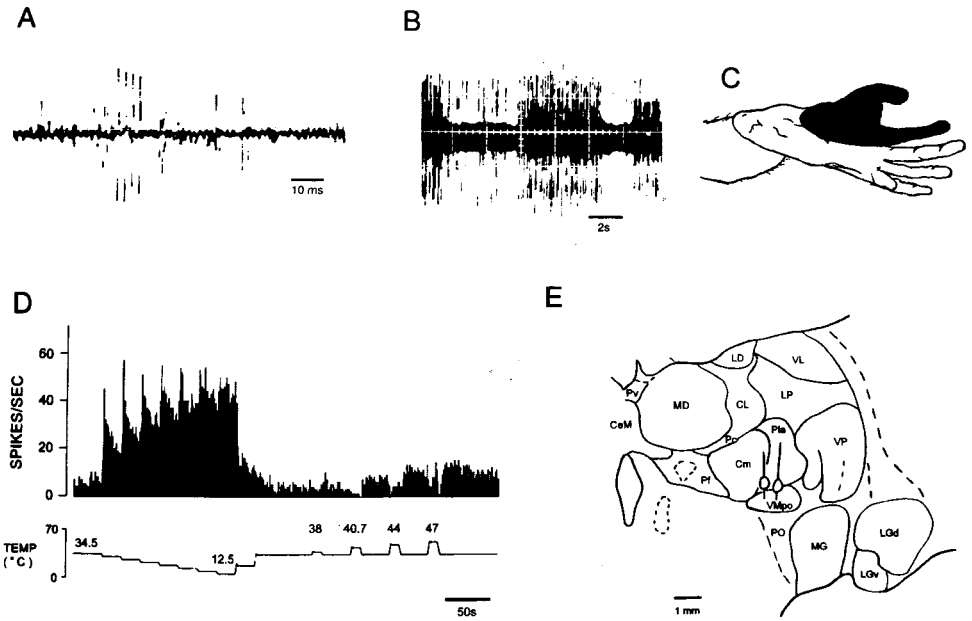

Figure 3. Responses of a lamina I spinothalamic tract neuron that was activated antidromically from the VMpo nucleus and that responded to cold thermoreceptors in the skin. The antidromic action potentials in (A) were in response to 4 stimuli delivered by the lateral of the 2 electrodes whose positions near the VMpo nucleus are shown in (E). (B) shows that the activity of the neuron was inhibited when radiant warmth was applied to the receptive field, which is shown in (C). In (D) are the responses of the neuron to progressive decreases in skin temperature (4° steps from 34.5°C to 12.5°C), as well as inhibition after warming pulses. When a noxious 47°C heat pulse was used, the neuron showed a "paradoxical" response to heat. The drawing in (E) is of a section through the posterior thalamus at the level of the VMpo nucleus. CeM, central medial nucleus; CL, central lateral nucleus; CM, centre median nucleus; LD, lateral dorsal nucleus; LGd, dorsal lateral geniculate nucleus; LGv, ventral lateral geniculate nucleus; LP, lateral posterior nucleus; MD, medial dorsal nucleus; MG, medial geniculate nucleus; Pf, parafascicular nucleus; Pla, anterior pulvinar nucleus; PO, posterior nuclei; PV, paraventricular nucleus; VL, ventral lateral nucleus; VMpo, posterior ventral medial nucleus; VP, ventral posterior group of nuclei. (From Dostrovsky JO, Craig AD: Cooling-specific spinothalamic neurons in the monkey. J Neurophysiol 76:3656-3665, 1996)

lateral funiculus (Fig. 4A) than those from lumbosacral levels (Fig 4B). It should be cautioned that the axons include not only ones destined to terminate in the thalamus but also lamina I projections to brain stem structures,[37,118] and it should be noted that relatively few lamina I axons were labeled in experiments in which "optimal" (restricted to lamina I) or "nominal" anterograde injections (restricted to laminae I and II) were used. The locations of the lamina I axons in general matched those determined for identified STT axons in the antidromic microstimulation mapping study by the Minnesota group.[129,131]

Craig[38] claims that the location of the axons of lamina I cells in the middle of the lateral funiculus explains the success of cordotomies that interrupt axons ascending in this area to produce the loss of pain and temperature sensations on the contralateral side of the body. However, Nathan et al[94] in a review of the cordotomy literature conclude that "In the thoracic cord, the operation has to transect the entire anterolateral quadrant to obtain analgesia throughout the body below the level of the incision." Fig 5 shows the relevant area that must be sectioned to produce complete cutaneous analgesia and thermanesthesia, according to Nathan et al.

Craig and his colleagues have described several classes of lamina I neurons in cats,[62] including nociceptive-specific, thermoreceptive-specific (cold) and polymodal nociceptive (heat, pinch, and cold) neurons. Intracellular labeling experiments suggest that most nociceptive-specific neurons have a fusiform shape, although some are multipolar. On the other hand, most cold cells are pyramidal in shape, and most polymodal neurons are multipolar. Primate spinothalamic lamina I neurons retrogradely labeled with cholera toxin subunit B have similar morphologies; fusiform, pyramidal, and multipolar neurons can all be recognized.[128] However, the correspondence between structure and function has not yet been verified in monkeys. Pyramidal and multipolar STT cells predominate in the enlargements and fusiform neurons in the thoracic cord. Although the retrograde injections were targeted at the nuclei presumed to receive the most substantial lamina I projections (VMpo, VPI, and MDvc), the analysis of the injection sites revealed that the retrograde label spread well into the VPL and VPM nuclei in 5 of the 6 cases. Furthermore, the injection of label into the proposed VMpo nucleus could have labeled fibers of passage destined for the ventral posterior nuclei. Thus, there is no convincing evidence that the retrogradely labeled lamina I STT cells examined by Zhang and Craig[128] projected to the targeted thalamic nuclei. On the basis of their inconclusive evidence, many lamina I STT cells could have projected to the VPL nucleus.

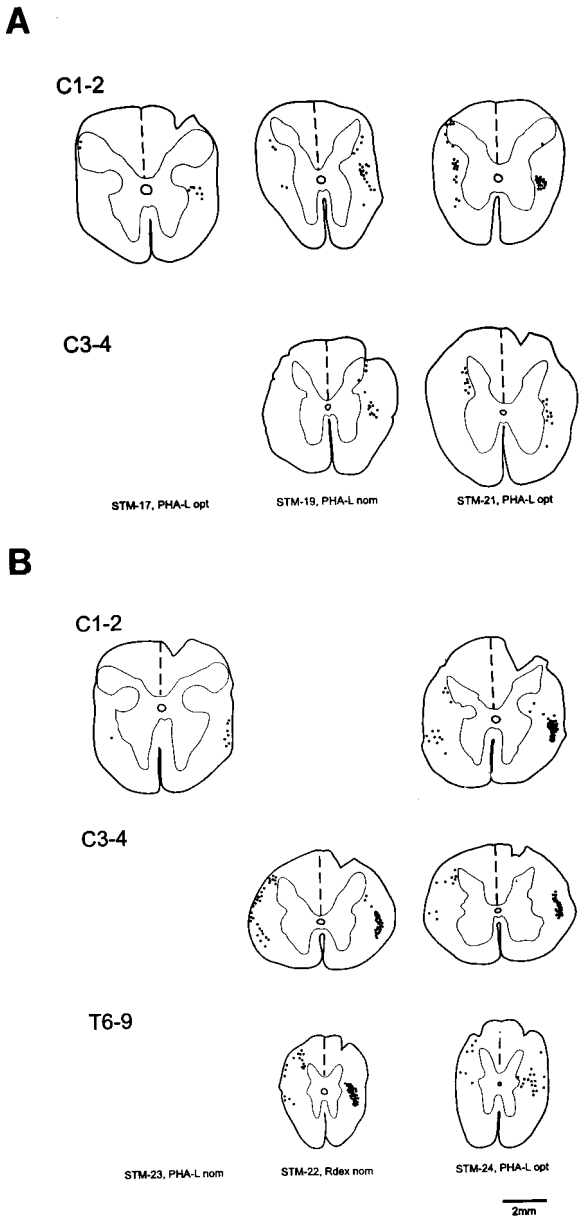

Figure 4. The locations of ascending axons of neurons of lamina I in the primate spinal cord white matter after labeling of the neurons by the injection of an anterograde tracer into the superficial dorsal horn. "Optimal" injections (opt) were confined to lamina I, whereas "nominal" (nom) injections were in laminae I and II. In (A) the injections were placed at cervical levels, whereas in (B) the injections were at a lumbar level. The locations of the axons are shown on transverse sections of the spinal cord at the indicated segmental levels. Axons that were contralateral to the injection are shown on the right side of each section, and those that were ipsilateral are shown on the left. The contralateral axons tend to form a compact bundle in the middle of the lateral funiculus. Axons arising from the cervical cord are medial to those arising from the lumbar cord. The ipilateral axons were suggested to include axons belonging to the spinocervical tract. (From Craig AD: Spinal location of ascending lamina I axons in the macaque monkey. J Pain 1:33-45, 2000)

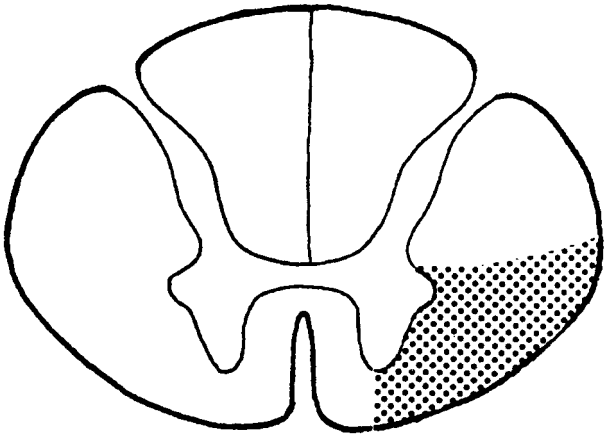

Figure 5. The area occupied by the spinothalamic tract complex (spinothalamic and other pain-associated ascending tracts) at a thoracic level in the human spinal cord, as determined based on the results of cordotomies performed for the relief of pain. The dotted area must be interrupted to produce compete analgesia and thermoanesthesia. (From Nathan PW, Smith M, Deacon P: The crossing of the spinothalamic tract. Brain 124:793-803, 2001. Reproduced by permission of Oxford University Press.)

Cortical Projections and Actions of VMpo

As mentioned, Craig et al[40] have proposed that the nucleus they term VMpo projects to the insula. With anterograde labeling, Craig et al[42] observed projections from the region of the proposed VMpo nucleus to the dorsal anterior insular cortex. There was also a small projection to SII, and in some animals a projection to area 3a of the SI somatosensory cortex was seen. However, this work is described in an abstract, and it does not appear to have been published as yet in full. Also an accompanying retrograde labeling study was not done. Thus, it is difficult to know to what extent the projections described actually originated in the proposed VMpo nucleus, rather than in adjacent parts of the thalamus, such as Po. Furthermore, there are no electrophysiologic studies in which neurons in VMpo have been antidromically activated from the insula.

A role of neurons in the region of the proposed VMpo nucleus in cold perception has been suggested,[46] because stimulation in the region of this nucleus in human subjects evokes a sensation of cold. Furthermore, thalamic neurons recorded in this region in humans respond to innocuous cooling, rather than to painful stimulation.[46] A projection of this nucleus to the insula could help explain the activation of the insula by cooling stimuli as seen by positron emission tomography.[41] Given the observation that cooling stimuli can activate neurons in the proposed VMpo nucleus and also cause activation of the insula in imaging studies, it might seem reasonable to attribute the cooling responses of the insula to this pathway.[41,45] However, the existence of a projection from the proposed VMpo nucleus to the insula needs additional experimental testing. For example, there has so far been no demonstration of the cortical projections of individual neurons in the region from which the recordings were made,[40,48] although the antidromic activation technique has been successfully used by others to dem-

onstrate the cortical projections of many types of thalamic neurons, including those that are nociceptive.

The results of studies in which neurons in thalamic nuclei were retrogradely labeled from different parts of the insula have been summarized.[55,92] Injections of horseradish peroxidase into the anterior insula label neurons in the VPMpc nucleus (also known as VMb), the magnocellular part of the medial dorsal nucleus and several intralaminar and midline thalamic nuclei. The posterior insula receives connections from the VPI, anterior and medial pulvinar, and supragenicular nuclei. In rats, there is also said to be an input to the insula from the VPL nucleus.[133] The SI and SII somatosensory cortices, as well as areas 5 and 7b, also all give rise to projections to the insula.[92] In addition, there are dense reciprocal projections between the insula and the basomedial and lateral nuclei of the amygdala.[92] Thus, the activation of the insula that has been observed in imaging studies could be accounted for not only by direct thalamic input but also by a neural pathway that involves the ventral posterior thalamus and thalamocortical projections from there to the SI and the SII somatosensory cortices and somatosensory association cortex. The observation by Ploner et al[100] (see below) that destruction of the SI and SII cortices eliminates the ability to detect thermal stimuli would be consistent with this interpretation. Alternatively, ascending spinal pathways that activate the amygdala could secondarily activate neurons in the insular cortex (see section on extrathalamic nociceptive pathways below).

In their positron emission tomography study, Craig et al[41] found a strong correlation between thermal stimulus intensity and the level of activation of the middle/posterior insular region. This led them to "interpret this region as the contralateral cortical representation of discriminative thermal sensation." However, different intensities of stimuli are likely to produce graded responses in a structure like the insula that may be involved in the memory of painful stimuli.[56] This study did not provide definitive evidence that the insula is involved in sensory discrimination of thermal stimuli. There was also activation of the posterior parietal cortex, which was attributed to "the attention directed to the right hand during the thermal stimuli." The specific part of the parietal cortex activated was not indicated, and there was no discussion of a possible role of the parietal cortex in thermal sensation. The possibility of a pathway that transmits cold responses processed in the posterior parietal cortex to the insula by way of SI and SII needs to be addressed.[100]

The insula is thought to play a role in pain,[132] but its functions are more likely to be related to asymbolia for pain, in which "patients recognize pain, but lack appropriate motor and emotional responses to painful stimuli. . ."[11] and to the memory of pain,[56,115] than to sensory-discrimination. Although a somatosensory function has been attributed to the insula, different parts of the insula function as visceral sensory, autonomic, and motor association areas, as well as regions involved in vestibular processing, language, limbic integration, working memory, and selective visual attention.[11,115]

Spinal Projection to MDvc and Responses of Intralaminar Neurons

Craig et al[40] refer to a projection of lamina I STT cells to the MDvc nucleus. This nucleus is presumably equivalent to the paralaminar part of MD that receives spinal projections and that many authors prefer to consider part of the CL nucleus.[69,91,93] Antidromic activation of STT cells from the CL nucleus has been reported,[3,59] but the STT cells were not concentrated in lamina I. Most were in the deep layers of the dorsal horn, the intermediate region, and the ventral horn. This distribution is consistent with that observed in a retrograde labeling study in which horseradish peroxidase was injected into the medial thalamus of monkeys.[123] These neurons often have very large receptive fields that are entirely unsuited for spatial discrimination[3,59] but that could contribute effectively to arousal and attentional mechanisms or other nondiscriminative functions, such as motivational-affective behavior. CL (and paralaminar) neurons that receive input from STT cells have been retrogradely labeled from the SI cortex.[60] Neurons have been described in the CL, CM, and parafascicular (Pf) nuclei that have large, usually bilateral receptive fields and that respond in a graded fashion to graded noxious heat stimuli.[24] The responses were altered by changes in the level of attention by the monkey to the stimulus or after administration of an anesthetic agent. Such responses of intralaminar neurons match well those of the STT cells that project to the medial but not to the lateral thalamus.[3,59] Fig 6 shows projections from the CL and Pf nuclei to the anterior cingulate gyrus.

The suggestion by Craig et al[40] that a projection from MDvc accounts for the activation of nociceptive neurons in the anterior cingulate gyrus after painful stimulation seems premature. The main thalamic inputs to the anterior cingulate gyrus are from the anterior nuclei, the parvocellular part of MD, as well as from a number of medial and intralaminar thalamic nuclei, including the CL and Pf nuclei.[117] Nociceptive neurons have been described in the anterior cingulate gyrus.[117] These neurons have properties similar to those of neurons in the CL and Pf nuclei that were mentioned above. Their receptive fields are large and bilateral, and the neurons respond to strong mechanical and often thermal stimuli. In at least some instances, the nociceptive responses of anterior cingulate neurons depend on information relayed through the Pf nucleus, because microinjections of lidocaine into Pf eliminates the responses.[117] Thus, the activation of the anterior cingulate gyrus by painful stimuli may depend chiefly on the discharges of spinothalamic projections from deep layers of the spinal gray matter to several intralaminar nuclei. The role of lamina I spinothalamic neurons may be minimal, although some of these cells do seem to project to the intralaminar region.[59] Another source of input to the intralaminar nuclei may be through spinoreticulothalamic projections.

Role of the Anterior Cingulate Gyrus in the Affective Dimension of Pain

There is considerable evidence from imaging studies that the anterior cingulate gyrus in humans is activated

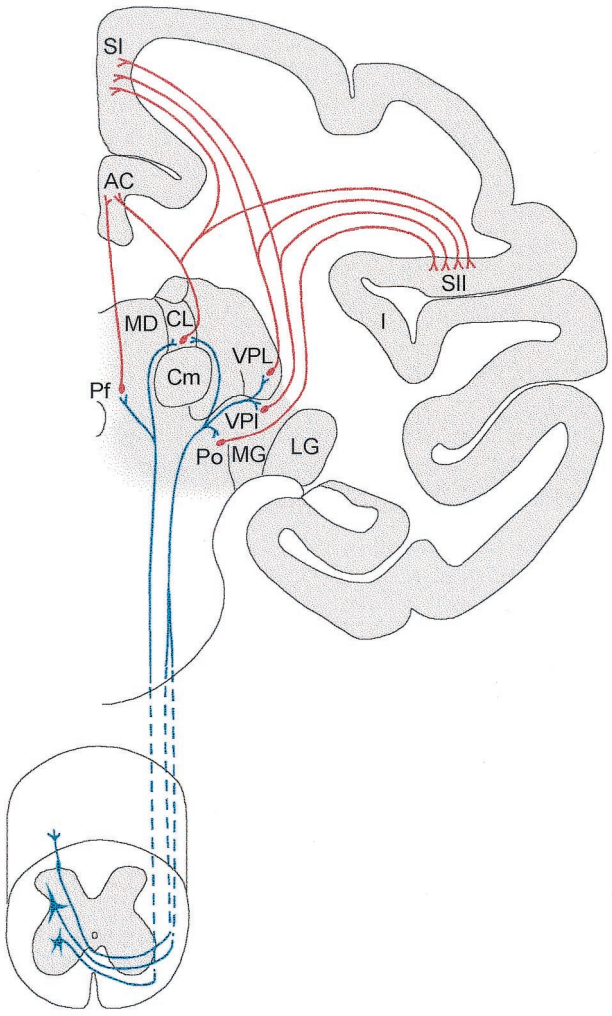

Figure 6. The drawing at the top shows a frontal section through the brain of a monkey at the level of the posterior thalamus. The positions of the SI (primary somatosensory), SII (secondary somatosensory), insular (I) and anterior cingulate (AC) cortices are indicated. Thalamic nuclei include CL, central lateral; CM, centre median; LG, lateral geniculate; MD, medial dorsal; MG, medial geniculate; Pf, parafascicular; Po, posterior; VPI, ventral posterior inferior; and VPL, ventral posterior lateral. The drawing of a transverse section of the lumbar spinal cord shows spinothalamic tract cells in laminae I, V and VII. Their axons cross to the contralateral side and ascend in the white matter to the thalamus. The axons of lamina I STT cells are located in the middle of the lateral funiculus, whereas those of laminae V and VII cells are located more ventrally. The axons of laminae I and V STT cells are shown to terminate in the VPL, VPI, Po and CL nuclei. The axons of lamina VII STT cells are shown to end in CL and Pf. VPL projects to SI and SII. VPI also projects to SII and SI. Po projects to SII. CL and Pf project to SI, SII and the anterior cingulate gyrus. The connections of the insula are not shown. The extrathalamic projections of spinal neurons, including those to the reticular formation, parabrachial region, hypothalamus, amygdala and other limbic structures, and the cortical connections of these structures are not shown.

by painful stimuli.[36,67,68,114] Furthermore, manipulations, such as hypnotic suggestion, indicate that the anterior cingulate gyrus is involved in the affective component of the response to pain.[106] Craig and Bushnell[39] have proposed that the differential discharges of lamina I spinothalamic tract neurons to innocuous versus noxious cold stimuli account for the thermal grill illusion, in which costimulation of the hand with alternating warm and cold metal bars is perceived as burning hot. An imaging study showed that the anterior cingulate cortex is activated during the thermal grill illusion.[43] However, there does not seem to be any evidence that excludes a role of neurons other than lamina I STT cells in the thermal grill illusion. In fact, at a recent meeting, Craig showed recordings from an STT cell in lamina V that responded in a manner that was consistent with a role of lamina V STT cells in the thermal grill illusion (Craig, unpublished, American Pain Society, 2000). If there is no projection of lamina V STT cells to the proposed VMpo nucleus, it follows that other regions of the thalamus may contribute to the illusion.

Evidence Concerning the Role of the Ventrobasal Complex and Somatosensory Cortex in Pain and Temperature Processing

Lamina I Projections to the Ventrobasal Complex

There is abundant evidence for a spinal pathway in monkeys to the VPL thalamic nucleus and from there to the SI and SII somatosensory cortex that can contribute to the sensory-discriminative analysis of painful stimuli. Furthermore, there are substantial projections from the SI and SII cortex and from the somatosensory association areas to the insula that could help account for the activation of insular cortex in imaging studies. The spinothalamic tract system in monkeys includes direct projections from STT cells to the VPL nucleus.[5,6,12,16,91,123] Similarly, the STT in humans terminates largely in the VPL nucleus, as well as in the CL nucleus[90] (Fig 7). However, it is unclear from these previous morphologic studies whether the STT projection to the VPL nucleus originates from lamina I or from deeper layers of the dorsal horn.

In electrophysiologic experiments, STT neurons located in both lamina I and in deeper layers of the dorsal horn in monkeys can be activated antidromically from the VPL nucleus, by using either relatively strong stimuli applied through an electrode placed in the VPL nucleus at the start of an experiment[32,51,95] or by using microstimulation with a roving electrode and very weak stimulus currents[9,129,131] (Fig 8). Similarly, trigeminothalamic neurons that can be activated antidromically from the VPM nucleus are located in the marginal zone and the magnocellular part of the trigeminal nucleus caudalis.[105]

Recently, we conducted a morphologic study to determine the distribution of STT and trigeminothalamic neurons that can be labeled after the injection of a retrograde tracer (cholera toxin subunit B) into the VPL and VPM nuclei.[126] The injection was restricted and did not spread to other thalamic nuclei that are known to receive a spinal projection (Fig 9A). Many labeled neurons were found in laminae I and IV to VI at all levels of the spinal cord, as well as in the comparable layers of the spinal nucleus of the trigeminal nerve, pars caudalis (Fig

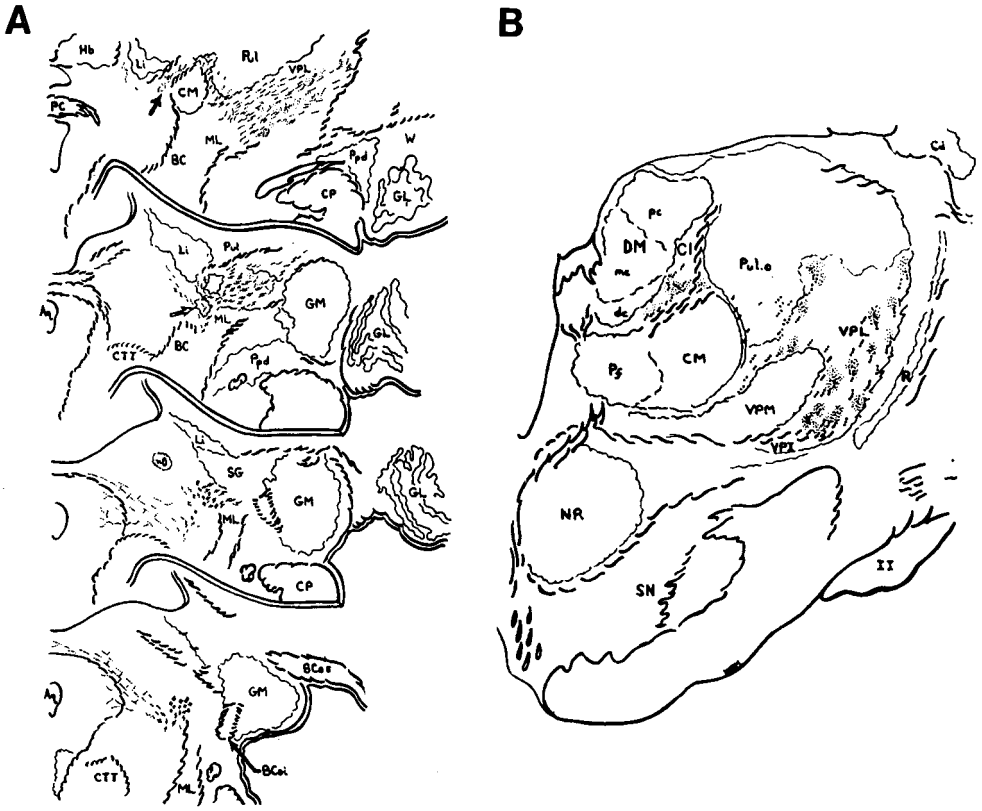

Figure 7. Anterograde degeneration of the spinothalamic tract in a patient who had had a successful cordotomy for the relief of intractable pain but who died 12 days after surgery. The brain stem and thalamus were sectioned and stained by the Nauta-Gygax silver degeneration technique. Nuclei were identified in adjacent Nissl stained sections. Fibers of passage are indicated for large dots and terminals by fine stipple. In (A) is shown a series of sections at the junction of the midbrain and caudal thalamus and (B) shows a section through the ventral posterior nuclei. Axons of passage are shown to pass through the region of the posterior complex and by the center median nucleus. Terminal zones are indicated in the VPL nucleus and to a lesser extent in the CL nucleus. Terminals in the posterior complex were thought to be on "the most caudal cells of the nucleus ventralis posterior lateralis (VPL)." Terminals in the VPL nucleus proper were scattered in an "archipelago" pattern, forming "pleiades" of terminal degeneration. Aq, cerebral aqueduct; BC, brachium conjunctivum; BCoi, brachium of the inferior colliculus; Bcos, brachium of the superior colliculus; Cd, caudate nucleus; Cl, central lateral nucleus; CM, centrum medianum nucleus; CP, cerebral peduncle; CTT, central tegmental tract; DM, dorsomedial nucleus (Pc, parvocellular part; Mc, magnocellular part; Dc, densocellular part); GL, lateral geniculate nucleus; GM, medial geniculate nucleus; Hb, habenula; Li, limitans nucleus; ML, medial lemniscus; nO, olivary pretectal nucleus; NR, red nucleus; PC, posterior commissure; Ppd, peripeduncular nucleus; Pul, pulvinar; Pulo, anterior pulvinar; R, reticular nucleus; SG, suprageniculate nucleus; SN, substantia nigra; VPI, ventral posterior inferior nucleus; VPL, ventral posterior lateral nucleus; VPM, ventral posterior medial nucleus; W, area triangularis of Wemicke II, optic nerve. (From Mehler WR: The anatomy of the so-called "pain tract" in man: An analysis of the course and distribution of the ascending fibers of the fasciculus anterolateralis, in French JD, Porter RW [eds]: Basic Research in Paraplegia. Thomas, Springfield, 1962, pp 26-55. Courtesy of Charles C Thomas, Publisher, Ltd, Springfield, Illinois.)

9B-D). This electrophysiologic and morphologic evidence does not contradict the positive findings in the studies by Craig and colleagues, but it does indicate a major oversight in the hypothetical organization of the spinothalamocortical pain system that they put forward (Fig 1), which entirely leaves out any consideration of a lamina I STT projection to the VPL nucleus. Furthermore, the role of nociceptive STT cells in deeper layers of the dorsal horn is virtually ignored, although Craig et al[40] do suggest that lamina V STT cells that relay in the VPL nucleus may account for activation of the SI cortex in experimental imaging studies of human pain. Fig 6 is a revised view of the spinothalamocortical pain system in which spinothalamic tract neurons of both lamina I and lamina V are shown to project to the VPL nucleus.

The receptive fields of lamina I STT neurons that project to the VPL nucleus tend to be smaller than those of STT cells in the deep layers of the dorsal horn,[51,120] suggesting that information from these neurons is especially important for stimulus localization. The distribution of the receptive field sizes of a sample of 204 STT cells located in lamina I or in laminae IV to VI and identified by antidromic activation from the VPL nucleus has been summarized.[120] For STT cells in lamina I, 85% of the receptive fields were very small or small, whereas for STT cells in laminae IV to VI, the receptive fields were evenly divided between small, medium, and large sizes. This distribution may in part reflect the fact that nociceptive-specific (NS) neurons in general have smaller receptive fields than do wide dynamic range (WDR) cells.[8,65] When the receptive field sizes of NS, WDR, and low threshold (LT) STT cells are compared, of a sample of 69 NS cells, 68% of the receptive fields were very small or small, whereas the receptive fields of most WDR cells were

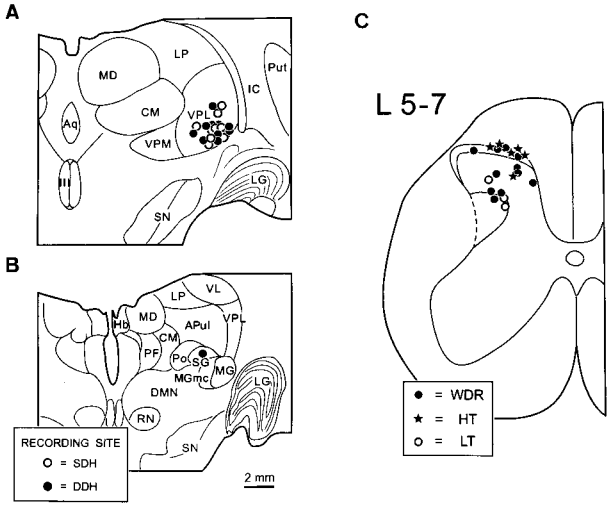

Figure 8. Projections of STT cells in lamina I and the deep layers of the dorsal horn to the VPL nucleus in monkeys. In (A) and (B), the locations are shown of low threshold sites (≤30 μA) in the thalamus from which STT cells could be activated antidromically. The open circles indicate stimulus points for antidromic activation of STT cells in the superficial dorsal horn (SDH), and the filled circles for STT cells in the deep dorsal horn (DDH). In (C) are shown the locations of the STT cells. Different symbols are used for WDR, high threshold (HT) and low threshold (LT) STT cells. (From Zhang X, Honda CN, Giesler GJ: Position of spinothalamic tract axons in upper cervical spinal cord of monkeys. J Neurophysiol 84:1180-1185, 2000)

evenly distributed between small, medium, and large sizes.

Another observation that suggests a particularly important role of lamina I STT cells in stimulus localization is that these neurons have a more clear-cut somatotopic organization than do STT neurons in deeper layers on the dorsal horn.[124] This may relate to the orientation of the dendrites of STT cells in lamina I. The dendrites of fusiform and multipolar lamina I neurons in rats are oriented chiefly longitudinally within the superficial dorsal horn,[86] although flattened and pyramidal neurons in lamina I have dendrites that extend both longitudinally and mediolaterally. The orientation of the dendrites of fusiform and multipolar lamina I neurons should give them an input consistent with the somatotopic map of the dorsal horn[122] and with the small receptive field sizes of many lamina I STT cells. By contrast, STT cells in the deep layers of the dorsal horn in monkeys often have dendrites that extend across much of the dorsal horn and dorsally as far as lamina I.[113] The dendrites of such neurons could presumably receive input from several dermatomes, thus accounting for the medium- to large-sized receptive fields of many of these cells.

In addition to stimulus localization, STT neurons that are involved in sensory-discrimination should be capable of responding differentially to different intensities of stimuli. They generally respond more strongly to noxious than to innocuous mechanical stimuli applied to the skin.[112] This feature is inherent in the definition of WDR

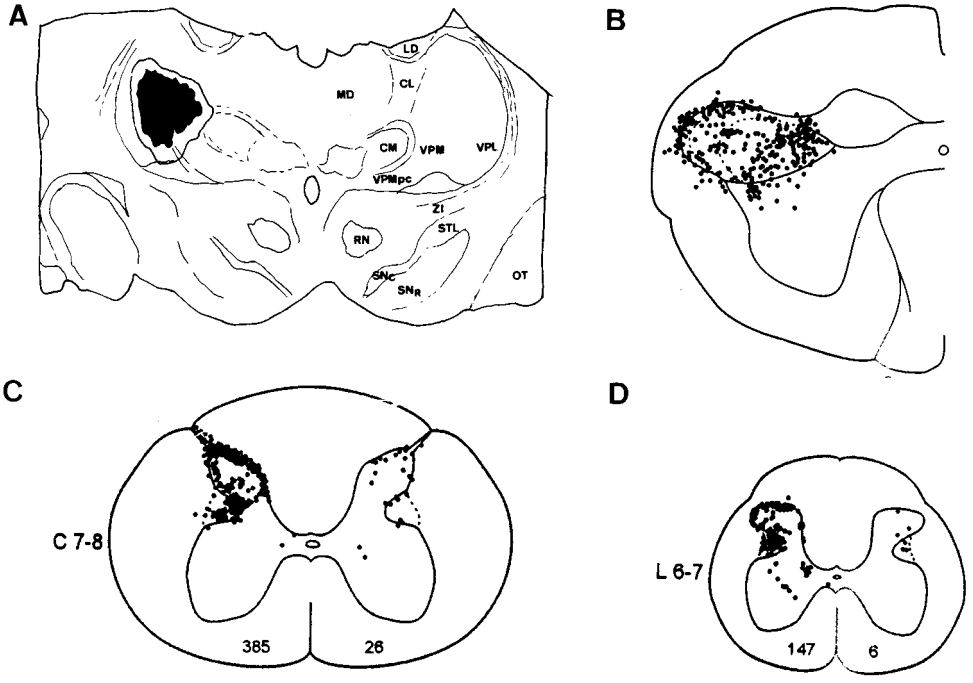

Figure 9. Retrograde labeling of laminae I and V STT cells and of similarly located trigeminothalamic neurons from the primate ventrobasal complex. Cholera toxin subunit B was used as the retrograde label. The injection site is shown in (A) to include parts of the VPL and VPM nuclei. There was some spread of the label into the lateral part of center median (CM) and into the VL nuclei. (B) shows the distribution of retrogradely labeled neurons in the caudal part of the spinal nucleus of the trigeminal nerve, and (C) and (D) show the distribution of labeled STT cells in the cervical and lumbar enlargements of the same monkey. (From Willis WD, Zhang X, Honda CN, Giesler GJ: Projections from the marginal zone and deep dorsal horn to the ventrobasal nuclei of the primate thalamus. Pain 92:267-276, 2001)

cells.[95] Furthermore, the STT cells that have the largest responses to graded mechanical stimuli are generally WDR cells.[95] Additional evidence for intensity coding comes from experiments on the responses of STT cells to graded noxious heat stimuli. Lamina I STT cells and STT cells in the deep layers of the dorsal horn that project to the VPL nucleus (as shown by antidromic activation) respond in a graded fashion to graded intensities of heat.[51,81,112] Visceroceptive STT cells also respond in a graded fashion to graded visceral stimuli, such as colorectal distention.[2] Trigeminal neurons that discriminate best between different intensities of noxious heat applied to the face in awake, behaving monkeys are a subpopulation of the WDR class.[25,49,76,87,88] These WDR medullary dorsal horn neurons can account for the ability of monkeys to perceive small differences in noxious heat stimuli, whereas NS neurons in the medullary dorsal horn cannot. The highly responsive WDR neurons included trigeminothalamic neurons identified by antidromic activation from the region of the VPM nucleus, and many were located in the marginal zone of the trigeminal nucleus caudalis.[88]

Nociceptive Responses of Neurons of the Ventrobasal Complex

Nociceptive responses have been recorded from neurons in the primate VPL nucleus.[7,18,29,30,33,34,57,78,99,102,121] Similarly, nociceptive neurons have been found in the VPM nucleus of monkeys.[23,27,50,127] Nociceptive neurons have also been recorded in the cutaneous core of the human VPL nucleus.[84,85]

The nociceptive responses of neurons in the VPL nucleus to noxious cutaneous stimuli are likely to reflect in part direct input from the spinothalamic tract, because lesions that presumably interrupt the spinothalamic tract often eliminate the responses.[33,78] However, part of the responses could be relayed through indirect pathways, including by way of corticothalamic feedback. Conversely, recordings have been made from neurons in the VPL nucleus that respond to noxious stimuli in monkeys with a lesion that interrupted the dorsal column and 1 ventrolateral column[99] or both the dorsal column and the spinocervical tract.[102] In the study by Pollin and Albe-Fessard,[102] awake, behaving monkeys were examined, and in the animals with spinal cord lesions all of the VPL neurons studied that had receptive fields on the hind limb responded to noxious stimulation of the skin. By contrast, visceral nociceptive responses in the VPL nucleus depend more on the dorsal column–medial lemniscus pathway than on the spinothalamic tract.[1]

Both WDR and NS types of nociceptive neurons can be found in the VPL nucleus[7,29,33,34,78] and in the VPM nucleus[25,27,88,105] of monkeys. More WDR than NS neurons are reported in several of these investigations. However, it is unclear whether this difference reflects the actual frequencies of these types of neurons in the thalamus, a sampling bias if the sizes of WDR and NS neurons differ, or, in the case of studies in awake, behaving animals, the impracticality of using strong stimuli. The receptive fields of nociceptive neurons in the VPL nucleus tend to be smaller than those of STT neurons,[33,78] although some are large or complex.[33] The nociceptive neurons in the VPL nucleus are somatotopically organized; those with receptive fields on the lower extremity are found in the lateral part of VPL and those with receptive fields on the upper extremity are in the medial part of VPL.[78] Nociceptive VPL neurons respond in a graded fashion to graded noxious mechanical and heat stimuli in a manner similar to that of STT cells,[33,34,78] although the heat responses of the thalamic neurons do not seem to adapt as rapidly as do those of STT cells.[78]

Spinal Projection to VPI and Responses of VPI Neurons

Craig et al[40] suggest that the input from lamina I STT cells that project to the VPI nucleus of the thalamus could account for the responses of the SII cortex to painful stimuli that are observed in imaging studies. However, similar to the nucleus they term VMpo, the VPI nucleus contains only scattered neurons. The VPI nucleus is "the main portal of entry of fibers of the medial lemniscus and brachium conjunctivum into the ventral nuclei;" "the greater part of its cell population is, therefore, glial."[69] Furthermore, many of the large cells in VPI near the border with VPL are regarded as clusters of VPL neurons that intrude into VPI nucleus.[73,90] Thus, it is difficult to be sure of the true boundary between these nuclei. Furthermore, given the concentration there of axons destined for the ventral thalamic nuclei, care may be needed to avoid mistaking recordings from axons for recordings from neuronal cell bodies. In Fig 6, collaterals of the axons of spinothalamic tract neurons in both laminae I and V are shown to synapse in the VPI nucleus.

Recordings have been made from nociceptive neurons in VPI.[7,102] The nociceptive VPI neurons were of either the WDR or NS type.[7] It is unclear whether these responses depended on input from STT cells in lamina V or I or whether they depended on other sources of input. The receptive fields seemed to have had a mediolateral somatotopic organization. The receptive fields were larger than those of neurons in VPL, and ventrally in VPI the receptive fields could be complex and discontinuous, and they could include the face.[7]

Thalamic Input to the SI Somatosensory Cortex

The VPL and VPM nuclei, which make up the ventrobasal complex of the thalamus, are the source of the main specific thalamocortical projection to the SI cortex.[69,70,111] Jones and Leavitt[72] and Jones et al[73] observed retrograde labeling of thalamic neurons after injections into the SI cortex only in the ventrobasal complex and in the CL nucleus of the intralaminar complex, and Friedman and Jones[54] found in anterograde tracing studies that the VPL nucleus projects to all 4 subdivisions of the SI cortex (areas 3a, 3b, 1, and 2). Several investigators have reported that neurons in thalamic nuclei other than the ventrobasal complex may also project

to SI.[44,60,103,111] Thus, the responses of neurons in SI to noxious stimuli are likely to be shaped largely by the responses of VPL and VPM neurons to such stimuli, although the responses may also depend to some extent on input from several other thalamic nuclei.

Craig et al[40] suggest that the activation of the SI cortex after painful stimulation can be attributed to the "multireceptive lamina V STT input to the ventral posterior lateral nucleus." However, as mentioned, a recent study by us[126] has demonstrated that lamina I STT and trigeminothalamic cells make a substantial projection to the VPL and VPM nuclei, along with that from STT and trigeminothalamic cells in the deep layers of the dorsal horn (Fig 9). Therefore, it seems reasonable to suggest that the nociceptive responses of neurons in SI depend largely on input from WDR and high threshold (HT) STT neurons in lamina I and the deep dorsal horn to the VPL nucleus and from cells in the comparable layers of the medullary dorsal horn to the VPM nucleus.

Nociceptive VPL neurons appear to project to area 1 of SI, because almost all of the nociceptive neurons in the VPL nucleus tested for antidromic activation from the cerebral cortex were backfired from SI, often from or subjacent to area 1[78] and nociceptive neurons in SI are concentrated in area 1.[79,80] The VPI nucleus has also been reported to project to the SI cortex,[60] as well as to SII,[55] and so it may well contribute to nociceptive responses in both areas of somatosensory cortex. However, no attempt was made by Apkarian and Shi[7] or by Pollin and Albe-Fessard[102] to activate the VPI neurons antidromically from their cortical targets, and so it is uncertain whether the recorded neurons in fact projected to the somatosensory cortex. Fig 6 shows projections from the VPL and VPI nuclei to the SI cortex.

Role of the SI Cortex in Sensory-Discrimination of Painful Stimuli

The importance of a projection of lamina I STT cells, as well as of STT cells in laminae IV to VI of the dorsal horn, to the VPL nucleus can be judged in reference to the likely role of the SI somatosensory cortex and its thalamocortical input from the ventrobasal thalamus in processing the sensory-discriminative aspects of pain. Despite earlier opinions to the contrary,[63,66,97] there is now strong evidence from human studies for an important contribution of the cerebral cortex to pain. In fact, imaging studies have revealed a number of different areas of the cerebral cortex that are activated in response to experimentally induced pain in human subjects, including the SI and SII regions of the somatosensory cortex, as well as the insula and the cingulate cortex.[26,28,36,45,58,67,68,106,114] For a time, it was thought that the SI region of the cerebral cortex was not importantly involved in pain.[63,66,97] This belief was based on clinical studies of patients who had lesions in only 1 of several areas of cortex now believed to contribute to the analysis of pain.[36]

Furthermore, there have been several reports of pain loss after restricted lesions of the SI cortex.[47,53,89,110] Ploner et al[100] recently reported a case in which the hand area of the SI and SII cortex was destroyed on the right side of the brain by a stroke. There was a loss of most sensations in the left hand and left arm, including the ability to distinguish between sharp and dull mechanical stimuli and to detect thermal stimuli. Not unexpectedly, there was also a loss of graphesthesia and stereognosis. Vibratory sense, as tested with a tuning fork, remained partially intact. Threshold for detection of nociceptive stimuli applied with a laser beam was elevated. When normally suprathreshold stimuli were given, the patient described a poorly localized unpleasant feeling somewhere between the shoulder and fingertips. Reaction times for the laser stimuli were prolonged in the left hand. It was concluded that the lesion affected preferentially the sensory-discrimination dimension of pain while leaving intact the motivational-affective component. The findings are consistent with a crucial role of the SI and SII cortex in the sensory-discrimination of painful stimuli. However, the patient also had an elevated threshold for affective responses, suggesting that these might depend, at least in part, on information that is processed in the SI and SII cortices and then transferred to limbic structures.[104] It should be noted that neurons in areas that are likely to mediate affective responses to painful stimuli, such as the medial thalamus[24] and limbic cortical areas,[35] can encode the intensity of noxious stimuli. The absence of thermal sensation on the side contralateral to the lesion in this patient argues strongly against an exclusive role of the insula in discriminative thermal sensation.[41] Perhaps the insula is activated secondarily by thermoresponsive neurons of the SI and SII cortices.

On the basis of experimental manipulations in imaging studies, it has been suggested that the SI cortex is involved in the localization of pain and the discrimination of pain intensity.[26] For example, activation of the SI cortex by noxious stimuli applied to either the hand or the foot shows that SI neurons with nociceptive responses are somatotopically organized.[4,26] When hypnosis is used to alter the perceived intensity of heat pain, activation in SI is modulated.[26] For example, if attention is diverted away from a painful stimulus, activation of the SI cortex is reduced. On the other hand, when hypnosis is used to alter the unpleasantness of pain, activation of the anterior cingulate gyrus is modulated without changes in the responses seen in the SI cortex.[106]

Within the SI cortex, painful heat stimuli produce the greatest activity in area 1.[58] Observations using magnetoencephalography confirm that the SI and SII cortices contribute to human pain responses[10,74,101] and reinforce the proposal of a particularly important role of area 1 within the SI cortex.[101] For additional evidence of the involvement of SI in pain, see reviews by Kenshalo and Willis[82] and Treede et al.[116]

There is also considerable evidence from animal experiments that the cerebral cortex, including SI, is involved in nociceptive processing. Lesions or cooling of the SI cortex reduce the responsiveness of awake, behaving monkeys to noxious stimuli.[17,77,96] Furthermore, record-

ings from neurons in area 1 of the SI cortex in anesthetized monkeys reveal the presence of nociceptive neurons.[31,77,79,80] These neurons can be of the WDR or of the NS type. They generally have small, contralateral receptive fields, they are somatotopically organized, and they are concentrated in layers III and IV.[80] It is not clear whether the small sizes of the receptive fields of SI neurons require an input from lamina I STT cells to the VPL nucleus or whether inhibitory interactions could enable such small receptive fields to be produced by input from lamina V STT cells. These neurons respond in a graded fashion to graded noxious heat stimuli and to intradermal injection of capsaicin, but not to innocuous cooling or stimulation of deep tissue.[80] In both awake, behaving monkeys and anesthetized monkeys, nociceptive neurons can be found in the face representation of the SI cortex that encodes the intensity of noxious thermal stimuli.[31,77] These properties of SI neurons in anesthetized and unanesthetized monkeys are consistent with a role of these SI cortical neurons in the sensory-discriminative aspects of pain.

The Role of the SII Cortex in Sensory-Discrimination of Pain

The SII cortex is also likely to be involved in the cortical processing of pain. The case recently reported by Ploner et al[100] is consistent with this idea, although the combined destruction of both the SI and SII cortices in this case makes it impossible to assess separately the roles of these 2 cortical regions. Other evidence from human studies includes the results of a number of imaging studies that demonstrate the activation of SII after painful stimuli.[28,36,45,114] Recordings from neurons in the SII cortex in awake, behaving monkeys are consistent with a role of the SII cortex in signaling pain.[109]

Thalamic nuclei that project to the SII cortex include VPL, VPI, Po, and CL,[55] and there is a substantial projection from the SI to the SII cortex.[56] All of these sources could provide nociceptive signals to the SII cortex. Fig 6 shows these connections.

Extrathalamic Pain Pathways

In addition to the spinothalamocortical pain pathways just reviewed, there are a number of nociceptive ascending pathways that can produce reactions to painful stimuli without necessarily relaying through the thalamus. These are pathways that can trigger autonomic, endocrine, emotional, and other responses, including the triggering of the endogenous analgesia systems, as part of the overall pain reaction. It is not the purpose of this review to discuss these pathways in detail.[119,122,125] However, they include the spinoreticular tracts,[37,61,83,90,91,118] the spinohypothalamic tract,[19,20,130] the spinoparabrachioamygdalar pathway,[13,14] the direct spinoamygdalar pathway, and other spinolimbic tracts.[19,21,22]

Conclusions

The evidence from our recent retrograde labeling study[126] and from previous electrophysiologic experiments in monkeys in several laboratories strongly supports the presence of a spinothalamocortical pathway from lamina I and deep layers of the dorsal horn to the contralateral VPL nucleus and from there to area 1 of the SI somatosensory cortex (Fig 6). This pathway is presumably important for transmitting information that leads to the sensory-discriminative aspects of pain sensation, including spatial location of painful stimuli and discrimination of stimulus intensity. A similar pathway may also be responsible for activation of nociceptive neurons in the SII cortex, because there are direct projections from the VPI and VPL nuclei to SII, as well as projections from SI to SII.

There are a number of ways by which neurons in the anterior cingulate cortex and the insula can be activated. It is unclear at present which pathway or pathways are most involved in the functions mediated by these cortical regions. The role of the spinal projection from lamina I to the nucleus referred to by Craig et al[40] as VMpo to the insula is unclear, as indeed is the very existence of this nucleus. The projection of CL and other intralaminar nuclei to the somatosensory and motor areas of the cortex may contribute to attentional mechanisms and arousal.

We hope that the review of the evidence will restore balance to presentations in neuroscience textbooks and reviews[52,75,98,104] of the spinothalamocortical pain system.

References

1. Al-Chaer ED, Feng Y, Willis WD: A role for the dorsal column in nociceptive visceral input into the thalamus of primates. J Neurophysiol 79:3143-3150, 1998

2. Al-Chaer ED, Feng Y, Willis WD: Comparative study of viscerosomatic input onto postsynaptic dorsal column and spinothalamic tract neurons in the primate. J Neurophysiol 82:1876-1882, 1999

3. Ammons WS, Girardot MN, Foreman RD: T2-T5 spinothalamic neurons projecting to medial thalamus with viscerosomatic input. J Neurophysiol 54:73-89, 1985

4. Andersson JL, Lilja A, Hartvig P, Langstrom B, Gordh T, Handwerker H, Torebjörk E: Somatotopic organization along the central sulcus, for pain localization in humans, as revealed by positron emission tomography. Exp Brain Res 117:192-199, 1997

5. Apkarian AV, Hodge CJ: Primate spinothalamic pathways: I. A quantitative study of the cells of origin of the spinothalamic pathway. J Comp Neurol 288:447-473, 1989

6. Apkarian AV, Hodge CJ: Primate spinothalamic pathways: III. Thalamic terminations of the dorsolateral and ventral spinothalamic pathways. J Comp Neurol 288:493-511, 1989

7. Apkarian AV, Shi T: Squirrel monkey lateral thalamus. I.

Somatic nociresponsive neurons and their relation to spinothalamic terminals. J Neurosci 14:6779-6795, 1994

8. Applebaum AE, Beall JE, Foreman RD, Willis WD: Organization and receptive fields of primate spinothalamic tract neurons. J Neurophysiol 8:572-586, 1975

9. Applebaum AE, Leonard RB, Kenshalo DR, Martin RF, Willis WD: Nuclei in which functionally identified spinothalamic tract neurons terminate. J Comp Neurol 188:575-586, 1979

10. Arendt-Nielsen L, Yamasaki H, Nielsen J, Naka D, Kakigi R: Magnetoencephalographic responses to painful impact stimulation. Brain Res 839:203-208, 1999

11. Augustine JR: Circuitry and functional aspects of the insular lobe in primates including humans. Brain Res Rev 22:229-244, 1996

12. Berkley KJ: Spatial relationships between the terminations of somatic sensory and motor pathways in the rostral brainstem of cats and monkeys. I. Ascending somatic sensory inputs to lateral diencephalon. J Comp Neurol 193:283-317, 1980

13. Bernard JF, Besson JM: The spino(trigemino)pontoamygdaloid pathway: Electrophysioloigical evidence for an involvement in pain processes. J Neurophysiol 63:473-490, 1990

14. Bernard JF, Dallel R, Raboisson P, Villanueva L, Le Bars D: Organization of the efferent projections from the spinal cervical enlargement to the parabrachial area and periaqueductal gray: A PHA-L study in the rat. J Comp Neurol 353:480-505, 1995

15. Blomqvist A, Zhang ET, Craig AD: Cytoarchitectonic and immunohistochemical characterization of a specific pain and temperature relay, the posterior portion of the ventral medial nucleus, in the human thalamus. Brain 123:601-619, 2000

16. Boivie J: An anatomical reinvestigation of the termination of the spinothalamic tract in the monkey. J Comp Neurol 186:343-370, 1979

17. Brinkman J, Colebatch JG, Porter R, York DH: Responses of precentral cells during cooling of post-central cortex in conscious monkeys. J Physiol 368:611-625, 1985

18. Brüggemann J, Shi T, Apkarian AV: Squirrel monkey lateral thalamus. II. Viscerosomatic convergent representation of urinary bladder, colon, and esophagus. J Neurosci 14: 6796-6814, 1994

19. Burstein R, Cliffer KD, Giesler GJ: Direct somatosensory projections from the spinal cord to the hypothalamus and telencephalon. J Neurosci 7:4159-4164, 1987

20. Burstein R, Cliffer KD, Giesler GJ: Cells of origin of the spinohypothalamic tract in the rat. J Comp Neurol 291:329-344, 1990

21. Burstein R, Giesler GJ: Retrograde labeling of neurons in spinal cord that project directly to nucleus accumbens or the septal nuclei in the rat. Brain Res 497:149-154, 1989

22. Burstein R, Potrebic S: Retrograde labeling of neurons in the spinal cord that project directly to the amygdala or the orbital cortex in the rat. J Comp Neurol 335:469-485, 1993

23. Bushnell MC, Duncan GH: Mechanical response properties of ventroposterior medial thalamic neurons in the alert monkey. Exp Brain Res 67:603-614, 1987

24. Bushnell MC, Duncan GH: Sensory and affective aspects of pain perception: Is medial thalamus restricted to emotional issues? Exp Brain Res 78:415-418, 1989

25. Bushnell MC, Duncan GH, Dubner R, He LF: Activity of trigeminothalamic neurons in medullary dorsal horn of awake monkeys trained in a thermal discrimination task. J Neurophysiol 52:170-187, 1984

26. Bushnell MC, Duncan GH, Hofbauer RK, Ha B, Chen JI, Carrier B: Pain perception: Is there a role for primary somatosensory cortex? Proc Natl Acad Sci USA 96:7705-7709, 1999

27. Bushnell MC, Duncan GH, Tremblay N: Thalamic VPM nucleus in the behaving monkey. I. Multimodal and discriminative properties of thermosensitive neurons. J Neurophysiol 69:739-752, 1993

28. Casey KL, Minoshima S, Morrow TJ, Koeppe RA: Comparison of human cerebral activation pattern during cutaneous warmth, heat pain and deep cold pain. J Neurophysiol 76: 571-581, 1996

29. Casey KL, Morrow TJ: Ventral posterior thalamic neurons differentially responsive to noxious stimulation of the awake monkey. Science 221:675-677, 1983

30. Chandler MJ, Hobbs SF, Fu QG, Kenshalo DR, Blair RW, Foreman RD: Responses of neurons in ventroposterolateral nucleus of primate thalamus to urinary bladder distension. Brain Res 571:26-34, 1992

31. Chudler EH, Anton F, Dubner R, Kenshalo DR: Responses of nociceptive SI neurons in monkeys and pain sensation in humans elicited by noxious thermal stimulation: Effect of interstimulus interval. J Neurophysiol 63:559-569, 1990

32. Chung JM, Kenshalo JM, Gerhart KD, Willis WD: Excitation of primate spinothalamic neurons by cutaneous C-fiber volleys. J Neurophysiol 42:1354-1369, 1979

33. Chung JM, Lee KH, Surmeier DJ, Sorkin LS, Kim J, Willis WD: Response characteristics of neurons in the ventral posterior lateral nucleus of the monkey thalamus. J Neurophysiol 56:370-390, 1986

34. Chung JM, Surmeier DJ, Lee KH, Sorkin LS, Honda CN, Tsong Y, Willis WD: Classification of primate spinothalamic and somatosensory thalamic neurons based on cluster analysis. J Neurophysiol 56:308-327, 1986

35. Coghill RC, Sang CN, Maisog JM, Iadorola MJ: Pain intensity processing within the human brain: A bilateral, distributed mechanism. J Neurophysiol 82:1934-1943, 1999

36. Coghill RC, Talbot JD, Evans AC, Meyer E, Gjedde A, Bushnell MC, Duncan GH: Distributed processing of pain and vibration by the human brain. J Neurosci 14:4095-4108, 1994

37. Craig AD: Distribution of brainstem projections from spinal lamina I neurons in the cat and monkey. J Comp Neurol 361:225-248, 1995

38. Craig AD: Spinal location of ascending lamina I axons in the macaque monkey. J Pain 1:33-45, 2000

39. Craig AD, Bushnell MC: The thermal grill illusion: Unmasking the burn of cold pain. Science 265:252-255, 1994

40. Craig AD, Bushnell MC, Zhang ET, Blomqvist A: A thalamic nucleus specific for pain and temperature sensation. Nature 372:770-773, 1994

41. Craig AD, Chen K, Bandy D, Reiman EM: Thermosensory activation of insular cortex. Nat Neurosci 3:184-190, 2000

42. Craig AD, Krout K, Zhang ET: Cortical projections of VM_{po}, a specific pain and temperature relay in primate thalamus. Soc Neurosci Abstr 21:1165, 1995

43. Craig AD, Reiman EM, Evans A, Bushnell MC: Functional imaging of an illusion of pain. Nature 384:258-260, 1996

44. Cusick CG, Gould HJ: Connections between area 3b of the somatosensory cortex and subdivisions of the ventroposterior nuclear complex and the anterior pulvinar nucleus in squirrel monkeys. J Comp Neurol 292:83-102, 1990

45. Davis KD, Kwan CL, Crawley AP, Mikulis DJ: Functional MRI study of thalamic and cortical activations evoked by cutaneous heat, cold, and tactile stimuli. J Neurophysiol 80: 1533-1546, 1998

46. Davis KD, Lozano RM, Manduch M, Tasker RR, Kiss ZH, Dostrovsky JO: Thalamic relay site for cold perception in humans. J Neurophysiol 81:1970-1973, 1999

47. Dejerine J, Mouzon J: Un nouveau type de syndrome sensitive cortical observe dans un cas de monoplegie corticale dissociee. Rev Neurol 28:1265-1271, 1915

48. Dostrovsky JO, Craig AD: Cooling-specific spinothalamic neurons in the monkey. J Neurophysiol 76:3656-3665, 1996

49. Dubner R, Kenshalo DR, Maixner W, Bushnell MC, Oliveras JL: The correlation of monkey medullary dorsal horn neuronal activity and the perceived intensity of noxious heat stimuli. J Neurophysiol 62:450-457, 1989

50. Duncan GH, Bushnell MC, Oliveras JL, Bastrash N, Tremblay N: Thalamic VPM nucleus in the behaving monkey. III. Effects of reversible inactivation by lidocaine on thermal and mechanical discrimination. J Neurophysiol 70:2086-2096, 1993

51. Ferrington DG, Sorkin LS, Willis WD: Responses of spinothalamic tract cells in the superficial dorsal horn of the primate lumbar spinal cord. J Physiol 388:681-703, 1987

52. Fields HL: Pain: An unpleasant topic. Pain Suppl 6:S61-69, 1999

53. Foerster O: Die Leitungsbahnen des Schmerzgefühls und die Chirurgische Behandlung der Schmerzzustände. Berlin, Germany, Urban and Schwarzenberg, 1927

54. Friedman DP, Jones EG: Thalamic input to areas 3a and 2 in monkeys. J Neurophysiol 45:59-85, 1981

55. Friedman DP, Murray EA: Thalamic connectivity of the second somatosensory area and neighboring somatosensory fields of the lateral sulcus of the macaque. J Comp Neurol 252:348-373, 1986

56. Friedman DP, Murray EA, O'Neill JB, Mishkin M: Cortical connections of the somatosensory fields of the lateral sulcus of macaques: Evidence for a corticolimbic pathway for touch. J Comp Neurol 252:323-347, 1986

57. Gaze RM, Gordon G: The representation of cutaneous sense in the thalamus of the cat and monkey. Q J Exp Physiol 39:279-304, 1954

58. Gelnar PA, Krauss BR, Sheehe PR, Szeverenyi NM, Apkarian AV: A comparative fMRI study of cortical representations for thermal painful, vibrotactile, and motor performance tasks. Neuroimage 10:460-482, 1999

59. Giesler GJ, Yezierski RP, Gerhart KD, Willis WD: Spinothalamic tract neurons that project to medial and/or lateral thalamic nuclei: Evidence for a physiologically novel population of spinal cord neurons. J Neurophysiol 46:1285-1308, 1981

60. Gingold SI, Greenspan JD, Apkarian AV: Anatomic evidence of nociceptive inputs to primary somatosensory cortex: Relationship between spinothalamic terminals and thalamocortical cells in squirrel monkeys. J Comp Neurol 308:467-490, 1991

61. Haber LH, Moore BD, Willis WD: Electrophysiological response properties of spinoreticular neurons in the monkey. J Comp Neurol 207:75-84, 1982

62. Han ZS, Zhang ET, Craig AD: Nociceptive and thermoreceptive laminma I neurons are anatomically distinct. Nat Neurosci 1:218-225, 1998

63. Head H, Holmes G: Sensory disturbances from cerebral lesions. Brain 34:102-254, 1911

64. Hirai T, Jones EG: A new parcellation of the human thalamus on the basis of histochemical staining. Brain Res Rev 14:1-34, 1989

65. Hoffman DS, Dubner R, Hayes RL, Medlin TP: Neuronal activity in medullary dorsal horn of awake monkeys trained in a thermal discrimination task. I. Responses to innocuous and noxious thermal stimuli. J Neurophysiol 6:409-427, 1981

66. Holmes G: Disorders of sensation produced by cortical lesions. Brain 50:413-427, 1927

67. Iadarola MJ, Berman KF, Zeffiro TA, Byas-Smith MG, Gracely RH, Max MB, Bennett GJ: Neural activation during acute capsaicin-evoked pain and allodynia assessed with PET. Brain 121:931-947, 1998

68. Jones AK, Brown WD, Friston KJ, Qi LY, Frackowiak RS: Cortical and subcortical localization of response to pain in man using positron emission tomography. Proc R Soc Lond B 244:39-44, 1991

69. Jones EG: The Thalamus. New York, NY, Plenum Press, 1985

70. Jones EG: A description of the human thalamus, in Steriade M, Jones EG, McCormick DA (eds): Thalamus, vol. II, Experimental and Clinical Aspects. Amsterdam, the Netherlands, Elsevier, 1997, pp 425-299

71. Jones EG: The primate nervous system, part II, in Björklund A, Hökfelt T (eds): Handbook of Chemical Neuroanatomy, vol 14. Amsterdam, the Netherlands, Elsevier, 1998, pp 1-298

72. Jones EG, Leavitt RY: Retrograde axonal transport and the demonstration of non-specific projections to the cerebral cortex and striatum from thalamic intralaminar nuclei in the rat, cat and monkey. J Comp Neurol 154:349-378, 1974

73. Jones EG, Wise SP, Coulter JD: Differential thalamic relationships of sensory-motor and parietal cortical fields in monkeys. J Comp Neurol 183:833-882, 1979

74. Kanda M, Nagamine T, Ikeda A, Ohara S, Kunieda T, Fujiwara N, Yazawa S, Sawamoto N, Matsumoto R, Taki W, Shibasaki H: Primary somatosensory cortex is actively involved in pain processing in humans. Brain Res 853:282-289, 2000

75. Kandel ER, Schwartz JH, Jessell TM: Principles of Neural Science, 4th ed. New York, NY, McGraw Hill, 2000

76. Kenshalo DR, Anton F, Dubner R: The detection and perceived intensity of noxious thermal stimuli in monkey and in human. J Neurophysiol 62:429-436, 1989

77. Kenshalo DR, Chudler EH, Anton F, Dubner R: SI nociceptive neurons participate in the encoding process by which monkeys perceive the intensity of noxious thermal stimulation. Brain Res 454:378-382, 1988

78. Kenshalo DR, Giesler GJ, Leonard RB, Willis WD: Responses of neurons in primate ventral posterior lateral nucleus to noxious stimuli. J Neurophysiol 43:1594-1614, 1980

79. Kenshalo DR, Isensee O: Responses of primate SI cortical neurons to noxious stimuli. J Neurophysiol 50:1479-1496, 1983

80. Kenshalo DR, Iwata K, Sholas M, Thomas DA: Response properties and organization of nociceptive neurons in area 1 of monkey primary somatosensory cortex. J Neurophysiol 84:719-729, 2000

81. Kenshalo DR, Leonard RB, Chung JM, Willis WD: Responses of primate spinothalamic neurons to graded and to repeated noxious heat stimuli. J Neurophysiol 42:1370-1389, 1979

82. Kenshalo DR, Willis WD: The role of the cerebral cortex in pain sensation, in Peters A, Jones EG (eds): Cerebral Cortex, vol 9, Normal and Altered States of Function. New York, NY, Plenum Press, 1991, pp 151-212

83. Kevetter GA, Haber LH, Yezierski RP, Chung JM, Martin RF, Willis WD: Cells of origin of the spinoreticular tract in the monkey. J Comp Neurol 207:61-74, 1982

84. Lenz FA, Dougherty PM: Pain processing in the human thalamus, in Steriade M, Jones EG, McCormick DA (eds): Thalamus, vol II, Experimental and Clinical Aspects. Amsterdam, the Netherlands, Elsevier, 1997, pp 617-651

85. Lenz FA, Gracely RH, Rowland LH, Dougherty PM: A population of cells in the human thalamic principal sensory nucleus respond to painful mechanical stimuli. Neurosci Lett 180:46-50, 1994

86. Lima D, Coimbra A: A Golgi study of the neuronal population of the marginal zone (lamina I) of the rat spinal cord. J Comp Neurol 244:53-71, 1986

87. Maixner W, Dubner R, Bushnell MC, Kenshalo DR, Oliveras JL: Wide-dynamic-range dorsal horn neurons participate in the encoding process by which monkeys perceive the intensity of noxious heat stimuli. Brain Res 374:385-388, 1986

88. Maixner W, Dubner R, Kenshalo DR, Bushnell MC, Oliveras JL: Responses of monkey medullary dorsal horn neurons during the detection of noxious heat stimuli. J Neurophysiol 62:437-449, 1989

89. Marshall J: Sensory disturbances in cortical wounds with special reference to pain. J Neurol Neurosurg Psychiat 14: 187-204, 1951

90. Mehler WR: The anatomy of the so-called "pain tract" in man: An analysis of the course and distribution of the ascending fibers of the fasciculus anterolateralis, in French JD, Porter RW (eds): Basic Research in Paraplegia. Thomas, Springfield, 1962, pp 26-55

91. Mehler WR, Feferman ME, Nauta WJH: Ascending axon degeneration following anterolateral cordotomy: An experimental study in the monkey. Brain 83:718-751, 1960

92. Mesulam MM, Mufson EJ: The insula of Reil in man and monkey: Architectonics, connectivity, and function, in Peters A, Jones EG (eds): Cerebral Cortex, vol. 4, Association and Auditory Cortices. New York, NY, Plenum Press, 1984, pp 179-226

93. Morel A, Magnin M, Jeanmonod D: Multiarchitectonic and stereotactic atlas of the human thalamus. J Comp Neurol 387:588-630, 1997

94. Nathan PW, Smith M, Deacon P: The crossing of the spinothalamic tract. Brain 124:793-803, 2001

95. Owens CM, Zhang D, Willis WD: Changes in the response states of primate spinothalamic tract cells caused by mechanical damage of the skin or activation of descending controls. J Neurophysiol 67:1509-1527, 1992

96. Peele TL: Acute and chronic parietal lobe ablations in monkeys. J Neurophysiol 7:269-286, 1944

97. Penfield W, Boldrey E: Somatic motor and sensory representation in the cerebral cortex of man as studied by electrical stimulation. Brain 60:389-443, 1937

98. Perl ER: Getting a line on pain: Is it mediated by dedicated pathways? Nat Neurosci 1:177-178, 1998

99. Perl ER, Whitlock DG: Somatic stimuli exciting spinothalamic projections to thalamic neurons in cat and monkey. Exp Neurol 3:256-296, 1961

100. Ploner M, Schmitz F, Freund HJ, Schnitzler A: Parallel activation of primary and secondary somatosensory cortices in human pain processing. J Neurophysiol 81:3100-3104, 1999

101. Ploner M, Schmitz F, Freund HJ, Schnitzler A: Differential organization of touch and pain in human primary somatosensory cortex. J Neurophysiol 83:1770-1776, 2000

102. Pollin B, Albe-Fessard D: Organization of somatic thalamus in monkeys with and without section of dorsal spinal tracts. Brain Res 173:431-449, 1979

103. Pons TP, Kaas JH: Connections of area 2 of somatosensory cortex with the anterior pulvinar and subdivisions of the ventroposterior complex in macaque monkeys. J Comp Neurol 240:16-36, 1985

104. Price DD: Psychological and neural mechanisms of the affective dimension of pain. Science 288:1769-1772, 2000

105. Price DD, Dubner R, Hu JW: Trigeminothalamic neurons in nucleus caudalis responsive to tactile, thermal, and nociceptive stimulation of monkey's face. J Neurophysiol 39:936-953, 1976

106. Rainville P, Duncan GH, Price DD, Carrier B, Bushnell MC: Pain affect encoded in human anterior cingulate but not somatosensory cortex. Science 277:968-971, 1997

107. Rausell E, Bae CS, Viñuela A, Huntley GW, Jones EG: Calbindin and parvalbumin cells in monkey VPL thalamic nucleus: Distribution, laminar cortical projections, and relations to spinothalamic terminations. J Neurosci 12:4088-4111, 1992

108. Rausell E, Jones EG: Histochemical and immunocytochemical compartments of the thalamic VPM nucleus in monkeys and their relationship to the representational map. J Neurosci 11:210-225, 1991

109. Robinson CJ, Burton H: Somatic submodality distribution within the second somatosensory (SII), 7b, retroinsular, postauditory, and granular insular cortical areas in *M fascicularis*. J Comp Neurol 192:93-108, 1980

110. Russell WR: Transient disturbances following gunshot wounds of the head. Brain 68:79-97, 1945

111. Shi T, Apkarian AV: Morphology of thalamocortical neurons projecting to the primary somatosensory cortex and their relationship to spinothalamic terminals in the squirrel monkey. J Comp Neurol 361:1-24, 1995

112. Surmeier DJ, Honda CN, Willis WD: Responses of primate spinothalamic neurons to noxious thermal stimulation of glabrous and hairy skin. J Neurophysiol 56:328-350, 1986

113. Surmeier DJ, Honda CN, Willis WD: Natural groupings of primate spinothalamic neurons based on cutaneous stimulation: Physiological and anatomical features. J Neurophysiol 59:833-860, 1988

114. Talbot JD, Marrett S, Evans AC, Meyer E, Bushnell MC, Duncan GH: Multiple representations of pain in human cerebral cortex. Science 251:1355-1358, 1991

115. Treede RD, Apkarian AV, Bromm B, Greenspan JD, Lenz FA: Cortical representation of pain: Functional characteriza-

tion of nociceptive areas near the lateral sulcus. Pain 87: 113-119, 2000

116. Treede RD, Kenshalo DR, Gracely RH, Jones AK: The cortical representation of pain. Pain 79:105-111, 1999

117. Vogt BA, Sikes RW, Vogt LJ: Anterior cingulate cortex and the medial pain system, in Vogt BA, Gabriel M (eds): Neurobiology of Cingulate Cortex and Limbic Thalamus: A Comprehensive Handbook. Boston, MA, Birkhäuser, 1993, pp 313-344

118. Westlund KN, Craig AD: Association of spinal lamina I projections with brainstem catecholamine neurons I the monkey. Exp Brain Res 110:151-162, 1996

119. Willis WD: The Pain System: The Neural Basis of Nociceptive Transmission in the Mammalian Nervous System. Basel, Switzerland, Karger, 1985

120. Willis WD: Neural mechanisms of pain discrimination, in Lund JS (ed): Sensory Processing in the Mammalian Brain: Neural Substrates and Experimental Strategies. New York, NY, Oxford University Press, 1989, pp 130-143

121. Willis WD: Nociceptive function of thalamic neurons, in Steriade M, Jones EG, McCormick DA (eds): Thalamus, vol II, Experimental and Clinical Aspects. Amsterdam, the Netherlands, Elsevier, 1997, pp 373-424

122. Willis WD, Coggeshall RE: Sensory Mechanisms of the Spinal Cord, 2nd ed. New York, NY, Plenum Press, 1991

123. Willis WD, Kenshalo DR, Leonard RB: The cells of origin of the primate spinothalamic tract. J Comp Neurol 188:543-574, 1979

124. Willis WD, Trevino DL, Coulter JD, Maunz RA: Responses of primate spinothalamic tract neurons to natural stimulation of hindlimb. J Neurophysiol 37:358-372, 1974

125. Willis WD, Westlund KN: Neuroanatomy of the pain system and of the pathways that modulate pain. J Clin Neurophysiol 14:2-31, 1997

126. Willis WD, Zhang X, Honda CN, Giesler GJ: Projections from the marginal zone and deep dorsal horn to the ventrobasal nuclei of the primate thalamus. Pain 92:267-276, 2001

127. Yokota T, Nishikawa Y, Koyama N: Distribution of trigeminal nociceptive neurons in nucleus ventralis posteromedialis of primates, in Dubner R, Gebhart GF, Bond MR (eds): Pain Research and Clinical Management, vol 3. Amsterdam, the Netherlands, Elsevier, 1988, pp 555-559

128. Zhang ET, Craig AD: Morphology and distribution of spinothalamic lamina I neurons in the monkey. J Neurosci 17:3274-3284, 1997

129. Zhang X, Honda CN, Giesler GJ: Position of spinothalamic tract axons in upper cervical spinal cord of monkeys. J Neurophysiol 84:1180-1185, 2000

130. Zhang X, Wenk HN, Gokin AP, Honda CN, Giesler GJ: Physiological studies of spinohypothalamic tract neurons in the lumbar enlargement of monkeys. J Neurophysiol 82: 1054-1058, 1999

131. Zhang X, Wenk HN, Honda CN, Giesler GJ: Locations of spinothalamic tract axons in cervical and thoracic spinal cord white matter in monkeys. J Neurophysiol 83:2869-2880, 2000

132. Zhang ZH, Dougherty PM, Oppenheimer SM: Monkey insular cortex neurons respond to baroreceptive and somatosensory convergent inputs. Neuroscience 94:351-360, 1999

133. Zhang ZH, Oppenheimer SM: Baroreceptive and somatosensory convergent thalamic neurons project to the posterior insular cortex in the rat. Brain Res 861:241-256, 2000